



Original article

Some of the effects of aqueous crude seed extract of *Datura stramonium* on the histology of the frontal cortex and hippocampus of sprague dawley rats

A.D. Adedayo^{a,*} and T.A. Adekilekun^b

^aDepartment of Anatomy, Faculty of Basic Medical Sciences, University of Ilorin, Ilorin, Nigeria

^bDepartment of Anatomy, College of Health Sciences, Osun State University, Osogbo, Osun Nigeria

*Corresponding author; Department of Anatomy, Faculty of Basic Medical Sciences, P. M. B. 1515, University of Ilorin, Ilorin, Nigeria, +23480-3844-1671/ +23480-7656-3746

ARTICLE INFO

ABSTRACT

Article history:

Received 13 May 2012

Accepted 15 June 2012

Available online 29 August 2012

Keywords:

Datura stramonium

Frontal cortex

Hippocampus

10% formol calcium

Cervical decapacitation

This study was carried out in order to investigate some of the effects of aqueous seed extract of *Datura stramonium* on the histology of the frontal cortex and hippocampus of Sprague Dawley rats as marker of toxicity. 16 adult male Sprague Dawley rats were used for this study. The rats were distributed into two groups (A and B). The rats in group B served as the treatment group and were administered with 300 mg/kg bwt of the aqueous seed extract of *D. stramonium* while the animals in group A which served as the control were administered with equal volume of phosphate buffered saline (PBS). The duration of administration was for fourteen days (14d). The rats were sacrificed using cervical decapacitation 3hrs after the last administration. The brains were excised from the skulls of the animals and were completely fixed in 10% formol calcium. 24 hours after fixation, the frontal cortices and the hippocampi were excised from the fixed brains and were processed for routine histological study using Hematoxylin and eosin (H&E) stains. Observations made from the permanent photomicrographs revealed alterations in the histoarchitecture of the frontal cortices and hippocampi of the rats. These findings provide evidence that suggest that the oral administration of aqueous seed extract of *D. stramonium* confers deleterious effects on the frontal cortices and hippocampi of Sprague Dawley rats.

1. Introduction

The use of medicinal plants (including fruits and seeds) in their natural unprocessed and unrefined form began when the first “intelligent animal” observed that certain plants altered particular body function (Katzung, 2004). Medicinal plants are plants that have at least one of their biochemical components and/or structural parts (flowers, leaves, stem, seeds, barks or roots) used for therapeutic purposes (Bruneton, 1993). Recently, medicinal plants have become of immense use in the treatment of different disease conditions, such as diabetes, malaria, and anemia (Fola, 1993) to mention but few. The availability and relatively cheaper cost of medicinal plants makes them more useful as therapeutic agents when compared to ‘modern’ medicines (Agbor and Ngogang, 2005; Agbor et al., 2005). The importance of medicinal plants, and the contribution of phytomedicine to the clinical well-being of a significant number of the world’s population, has attracted interest from a variety of disciplines (Trease GE and Evans, 1996; Darias, 1986).

The folklore and medicinal potentials of *Datura stramonium* as a traditional herb are well documented from various researches and studies. Hirschmann *et al* (1990) stated in their study that the mixture of the leaves and seeds of *D. stramonium* taken orally as a decoction or smoke is used as a medicinal cure for asthma. Few of the other reported medicinal uses of the plant include; the anti-inflammatory property of all part of the plants (Spring, 1989), stimulation of central nervous system (CNS) (Guharov and Barajas, 1991; Manandhar, 1995), respiratory decongestion (Zagari, 1992), treatment of skin infections (John, 1984; De Foe and Senatore, 1993) and also in the treatment of dental decay (Abebe, 1986) and hair loss such as alopecia (Giral Hidalgo, 1983).

D. stramonium is a shrub that is widely distributed all over the world including Nigeria in West Africa. Locally the plant is known as ‘Gegemu’ in Yoruba. Phytochemicals analysis of the plant shows that it contains alkaloids atropine and scopolamine (El-Tawil, 1983), carotenes and coumarines (Aynehchi et al., 1985) and saponins (Modawi et al., 1985).

Addiction of youths to tolerable doses of leaves, flowers and seeds preparations has been encountered (Perry, 1980; Weiss, 1996) and this has pose serious threat to the health of the abused users.

The use of any medication be it folklore, herbal preparation, alternative therapy or synthetic is usually associated with unwanted effects, which are commonly known as side effects. The induced unwanted changes may affect the structural, cytochemical and functional capacities of the various affected organs. It is very crucial and important to direct the focus of attention toward vital organs in the body. This present study was undertaken in order to elucidate some of the effects of aqueous seed extract of *D. stramonium* on the frontal cortex and hippocampus of male Sprague Dawley rats.

2. Materials and methods

2.1. Animal care

Sixteen male Sprague Dawley rats of the first filial generation weighing between 160-190 g were used for this study. The rats were randomly assigned into two groups designated as A and B. The rat in the group B served as the treated group while the rats in group A served as the control. The rats were treated in accordance with the “Guide for the Care and Use of Laboratory Animals” prepared by the National Academy of Sciences and published by the National Institutes of Health” (DHEW Publication, 1996). The rats were fed with standard rat pellets obtained from J.D Adekomi Animals Feed Mill, Gbongan-Ibadan Express Way, Osogbo, Osun State, Nigeria through out the duration of the study at a recommended dose of 100 g/kg as advised by the International Centre of Diarrheal Disease Research, Bangladesh (ICDDR, B). Fresh drinking water was supplied *ad libitum*.

2.2. Preparation of plant extracts

Fresh unripe fruits of *D. stramonium* (weighing about 70-110 g in weight) were plucked from the plant at an uncultivated site at Ataoja Estate, Gbongan-Ibadan Express Way, Osogbo, Osun State and were authenticated at the Department of Plant Science University of Ilorin, Nigeria. The fruits of the plant were macerated and the seeds were air-dried for a period of 37d, the dried sample was grinded to powdery form with an electronic blender

(model MS - 223, China). The powdered seed material was measured using Gallenkomp (FA2104A, England) electronic weighing balance.

Four hundred grams of the grinded seed sample was later soaked in 900 ml of PBS for 72 hours (Wannang et al., 2009) at room temperature, and then filtered through silk cloth, after which the filtrate was again filtered with Whatman's #1 filter paper. The final filtrate was concentrated using a Rotary evaporator (Rotavapor® R-210). The residue of the extract obtained was kept in a capped sample bottle and stored in a refrigerator until used.

2.3. Animal treatment

The rats in the treatment group B were administered with 300 mg/kg body weight of the aqueous seed extract of *D. stramonium* once daily (07:00–07:45 h) using orogastric tube, while the rats in the control group A were administered with equal volume of PBS for 14d respectively. Three hour after the last administration, all the rats were sacrificed using cervical dislocation. The brains of the rats were excised from their skulls and were completely fixed in 10% formol calcium for 24 hours after which the frontal cortex and hippocampus was excised from the fixed brain and were processed for further routine histological study.

2.4. Histological procedure

After fixation in 10% formol calcium, the histological study for the frontal cortex and hippocampus was carried out using the method of Carleton (Carleton, 1967). The tissues were subjected to H&E staining procedures and the histological examination was done with the aid of the Olympus binocular light research microscope (XSZ-107BN, No. 071771). The permanent photomicrograph of each slide was taken with a Kodak Digital Camera (Kodak Easyshare C183) for subsequent histological analysis.

3. Results

3.1. Microscopic Observations

When the processed histological sections of the frontal cortex and hippocampus obtained from the rats in the treated group were viewed under the microscope, it was observed that the sections of all the rats in the treated group does not to conform to normal histological outline; there were observable necrosis, degeneration, distortment, derangement and vacuolations of the cells in the frontal cortex and hippocampus when compared with the control (Figs. 1-4).

4. Discussion

It has been reported that all parts of *D. stramonium* are poisonous if ingested by humans or livestock (Radford et al., 1964). Some of the effects of aqueous seed extract *D. stramonium* on the frontal cortex and hippocampus of male Sprague Dawley rats has not been studied. In this study, we investigated some of the effects of the aqueous seed extract of *D. stramonium* on the histology of the frontal cortex and hippocampus of male Sprague Dawley rats to elucidate some of the possible histological implications that could occur following its consumption.

The major outcome of this study revealed that oral administration of the aqueous seed extract of *D. stramonium* has disruptive effects on the histological profile of the frontal cortex and hippocampus of the rats treated with 300 mg/kg body weight of the aqueous seed extract of *D. stramonium* for 14d as there were histological derangement, degenerative changes, vacuolations and progressive cell death of the cells within the frontal cortex and hippocampus of the histological sections of the treated rats when compared with the sections obtained from the control group. The result confirmed previous studies indicating that all part of *D. stramonium* has toxic effect (Anozie, 1986; Gidado et al., 2001; Soneral and Connor, 2005).

The histological observations recorded in this study suggest that the pattern of cell death within the frontal cortex and hippocampus of the rats in the treated group could be as a result of deleterious effect(s) of the phytochemicals agents (tropane alkaloids) present in the seed extract. The outcome of this study is in support of the study of Adekomi et al (2011), Oberndorfer et al (2002), Roblot et al (1995) and Ertekin et al (2005).

5. Conclusion

In this study, we have demonstrated that oral administration of the aqueous seed extract of *D. stramonium* has neurodegenerative effects on the histological outline of the frontal cortex and hippocampus of male Sprague Dawley rats in the extract treated group. The side effects recorded in this study should be made available to consumers.

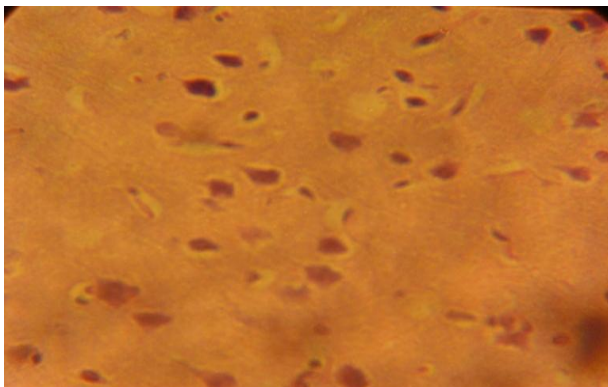


Fig. 1. Photomicrograph of the hippocampus of the rats in group A. (H&E x400).

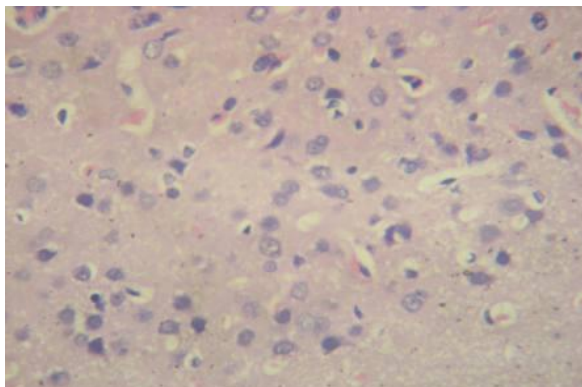


Fig. 2. Photomicrograph of the hippocampus of the rats in group B. (H&E x400).

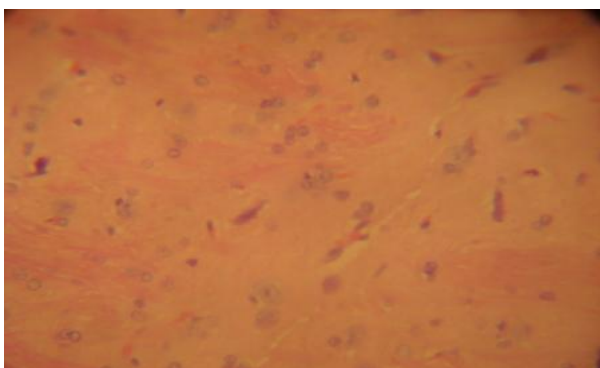


Fig. 3. Photomicrograph of the frontal cortex of the rats in group A (H&E x400).

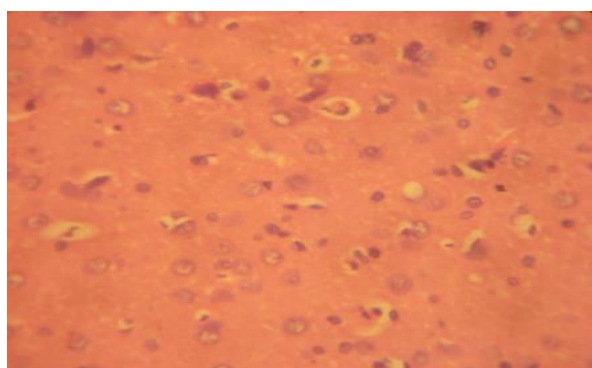


Fig. 4. Photomicrograph of the frontal cortex of the rats in group B. (H&E x400).

References

- Abebe, W., 1986. A survey of prescriptions used in traditional medicine in Gondar region, North-West Ethiopia: general pharmaceutical practice. *J. Ethnopharmacol.* 18, 147-165.
- Adekomi, D.A., Musa, A.A., Tijani, A.A., Adeniyi, T.D., Usman, B., 2011. Exposure to smoke extract of *Datura stramonium* leaf: Some of its effects on the heart, liver, lungs, kidneys and testes of male Sprague Dawley rats. *J. Pharmacog. Phyto.* 3, 67-75.
- Agbor, A.G., Ngogang, Y.J., Toxicity of herbal preparations. *Cam. J. Ethnobot.* 1, 23-28.
- Agbor, A.G., Oben, J.E., Ngogang, J.Y., 2005. Haematinic activity of *Hibiscus cannabinus*. *Afr. J. Biotechnol.* 4, 833-837.
- Anozie VC. Pharmacognostic studies on *Datura metel* Linn. Macro- morphology and micro-morphology of fruits and seed: *Herba Polonica* 1986; 32: 197 – 208
- Aynehchi, Y.S., Sormaghi, M.A., Amin, G.H., Khaskhow, M., Shabani, A., 1985. Survey of Iranian plants for saponins, alkaloids, flavanoids and tannins. *Int. J. Crude Drug. Res.* 23, 33-41.
- Bruneton, J., 1993. *Plantes Médicinales: Phytochimie, Pharmacognosie*, 2^{ème} Ed. New York: Lavoisier. 914.
- Carleton H. Carleton's histological technique. 4th Ed. Oxford University Press, 1967; 33-280.

- Darias, V., Brovo, L., Barquin, E., Horrera, D.M., Fraile, C., 1986. Contribution to the Ethnopharmacological study of the Canary Islands. *J. Ethnopharmacol.* 18, 169-193.
- De Foe, V., Senatore, F., 1993. Medicinal plants and phytotherapy in the Amal Fitan Cost, Salerno province Campania, Southern Italy. *J. Ethnopharmacol.* 39, 39-51.
- DHEW Publication (NIH), 1996. National Institute of Health Guide for the Care and Use of Laboratory Animals, revised, Office of Science and Health Reports, DRR/NIH, Bethesda, USA.
- El-Tawil, B.A.H., 1983. Chemical constituents of indigenous plant used in native medicine in Saudi Arabia. *Arab Gulf J. Sci. Res.* 12, 395-419.
- Ertekin, V., Selimoglu, M.A., Altinkaynak, S.A., 2005. Combination of unusual presentations of *Datura stramonium* intoxication in a child: Rhabdomyolysis and fulminant hepatitis. *J. Emerg. Med.* 28, 227-228.
- Fola, A., 1993. Local medicinal plants and the health of the consumers. A paper delivered at the PSN/CF PCON organization workshop: in *Clinical Pharmacy and Herbal Medicine.* 9, 28-31.
- Gidado, A., Bashirat, J.Y., Gana, G.M., Ambi, A.A., Milala, M.A., Zanna, H., 2001. Effects of aqueous extracts of the seeds of *Datura stramonium* on some indices of liver and kidney function in rats. *Nig. J. Exptl. Appl. Biol.* 2, 123-127.
- Giral, F., Hidalgo, C.C., 1983. Presence of alkaloids in Mexican plants. *Int. J. Crude Drug Res.* 21, 1-13.
- Guharov, S.R., Barajas, M., 1991. Intense stimulant effect: atropine intoxication from the ingestion and smoking of Jimson weed (*Datura stramonium*). *Vet. Toxicol.* 33, 588-58.
- Hirschmann, G.S., 1990. Rojas DC and Arias A. A survey of medicinal plants of Minas Gerais, Brazil. *J. Ethnopharmacol.* 29, 159-172.
- John, D., 1984. One hundred useful drugs of the Kani tribes of Trivandum forest divisions, Kerala, India. *Inter. J. Crude Drug Res.* 1984, 22:17-39.
- Katzung, B.G., 2004. *Basic and Clinical Pharmacology*, 9th Edition. New York: McGraw Hill Medical.
- Manandhar, N.P., 1995. Inventory of some herbal drugs of Myagai District, Nepal. *Econ. Bot.* 49, 371-379
- Modawi, B.M., Iskander, G.M., Karim, M.A., 1985. Steroidal components in plants of Sudan flora and seed germination; effects of withaobtusifonalide and withaphysanolide on *Eruka sativum*. *Fitoterapia.* 56, 5355.
- Oberndorfer, S., Grisold, W., Hinterholzer, G., Rosner, M., 2002. Coma with focal neurological signs caused by *Datura stramonium* intoxication in a young man. *J. Neurol. Neurosur. Psych.* 73, 458-459.
- Perry, L., 1980. *Medicinal plants of East and Southeast Asia.* Cambridge: MIT Press.
- Radford AE, Ahles HE, and Bell CR. *Manual of the Vascular Flora of the Carolinas.* University of North Carolina Press, Chapel Hill. 1964
- Roblot, F., Montaz, L., Delcoustal, M., Gaboriau, E., Chavagnat, J.J., Morichaud, G., 1995. *Datura stramonium* poisoning: The diagnosis is clinical, treatment is symptomatic. *Revue de Medecine Interne.* 16, 187-190.
- Sonerai, S.N., Connor, N.P., 2005. Jimson weed intoxication in five adolescents. *West Med. J.* 104, 70-72.
- Spring, M.A., 1989. Ethnopharmacologic analysis of medicinal plants used by Laotian Hmong refugees in Minnesota. *J. Ethnopharmacol.* 26, 65-91.
- Trease, G.E., Evans, W.C., 1996. *Photochemistry of plants.* In: *Pharmacognosy.* 14th Edition. Oxford: Alden Press. 213-232.
- Wannang, N.N., Ndukwe, H.C., Nnabuife, C., 2009. Evaluation of the analgesic properties of the *Datura metel* seeds aqueous extract. *J. Med. Plants Res.* 3, 192-195.
- Weiss, R., 1996. *Herbal Medicine.* Beaconsfield: Beaconsfield Publishers Ltd.
- Zagari, A., 1992. *Medicinal Plants*, Vol. 3, 5th ed. Tehran University Publication, No. 1810/3, Tehran, Iran, 889.